

Movement analysis in infancy may be useful for early diagnosis of autism

PHILIP TEITELBAUM*[†], OSNAT TEITELBAUM*, JENNIFER NYE*, JOSHUA FRYMAN*, AND RALPH G. MAURER[‡]

Departments of *Psychology and [‡]Child Psychiatry, University of Florida, Gainesville, FL 32611

Contributed by Philip Teitelbaum, September 17, 1998

ABSTRACT All of the 17 autistic children studied in the present paper showed disturbances of movement that with our methods could be detected clearly at the age of 4–6 months, and sometimes even at birth. We used the Eshkol–Wachman Movement Analysis System in combination with still-frame videodisc analysis to study videos obtained from parents of children who had been diagnosed as autistic by conventional methods, usually around 3 years old. The videos showed their behaviors when they were infants, long before they had been diagnosed as autistic. The movement disorders varied from child to child. Disturbances were revealed in the shape of the mouth and in some or all of the milestones of development, including, lying, righting, sitting, crawling, and walking. Our findings support the view that movement disturbances play an intrinsic part in the phenomenon of autism, that they are present at birth, and that they can be used to diagnose the presence of autism in the first few months of life. They indicate the need for the development of methods of therapy to be applied from the first few months of life in autism.

There is controversy over whether movement disorders play a central role in the phenomenon of autism and even whether such movement disorders exist in autism at all. For instance, Rimland (1) has stated:

It has been widely recognized for many decades that the vast majority of autistic persons are quite unimpaired with regard to their finger dexterity and gross motor capabilities. They have in fact often been described as especially dexterous and coordinated. The literature abounds with stories of young autistic children who can take apart and reassemble small mechanical devices, build towers of blocks and dominos higher than a normal adult can, assemble jigsaw puzzles and climb to dangerously high places without falling. . . The idea that autism is, or typically involves, a “movement disorder” is simply ludicrous . . .

On the other hand, Damasio and Maurer (2) and Vilensky *et al.* (3) showed that autistic children between the ages of 3 and 10 walk somewhat like Parkinsonian adults in that they walk more slowly than normal, with shorter steps. Correspondingly, Courchesne *et al.* (4), using MRI, have shown that certain areas of the cerebellar vermis are incompletely developed in autistic children [but see Piven (5)]. This also supports the view that movement disorders might play a role in autism (6, 7).

We believe that the findings presented here help to resolve this controversy. We used Eshkol–Wachman Movement Analysis in combination with flicker-free laser-disc still-frame analysis to study videos taken in infancy of 17 children who later turned out to be autistic, as diagnosed at the age of 3 years or older by conventional methods of diagnosis. Every one of these children displayed movement disorders, some subtle, some obvious.

Furthermore, because these movement disorders always could be detected with our methods as early as 4–6 months of age and

sometimes as early as the first few days after birth, we suggest that the study of movement disorders in infancy may serve as an earlier indicator than presently available methods for diagnosing autism in children.

As a framework for the study of infant movement, we decided to analyze the movements involved in the major motor milestones in the development of the baby from birth through the time that he or she starts to walk: i.e., lying, righting, sitting, crawling, standing, and walking. Every child goes through these stages (infants with severe neurological defects who are unable to progress through these stages of development are not included in the present discussion). Therefore, these motor milestones can serve as a common denominator by which to evaluate and compare normal and disintegrated movement in infants.

METHODS

We advertised in the monthly periodical published by the National Committee on Autism and in the e-mail list run by the Autism Society of America. We asked parents of autistic children (diagnosed by conventional methods usually at 3 years or older) to send us videos of their children taken when they were infants. We received and copied videos of 17 such infants and compared their patterns of lying (prone and supine), righting from their back to their stomach, sitting, crawling, standing, and walking with that of 15 normal infants. The normal infants were filmed by us in the nurseries of Kibbutz Merhavia in Israel when each pattern was just beginning to develop. Selected portions of these behaviors were transferred to videodisc (Panasonic Rewritable Optical Disc Recorder LQ-4000, Secaucus, NJ) for still-frame analysis by using Eshkol–Wachman Movement Notation (8). Eshkol–Wachman Movement Notation is a general analysis system in which spherical coordinates are applied independently to each segment of the body. By distinguishing between which segments are actively moving versus those that are being carried passively along, a deeper understanding of abnormal movement is possible.

RESULTS

Motor Milestones in Development

Lying. Lying is an active posture, even in the first few days of life. As has been pointed out by Caser (9), a newborn baby maintains specific active postures while lying. Persistent deviations from the normal patterns of lying can indicate abnormalities associated with autism. For instance, one of the children in the present study showed a persistent asymmetry[§] at the age of 4 months when lying on his stomach. His right arm always was caught under his chest, and even when engaged in reaching for an object with the other arm, he still did not use his right arm. Throughout his first year, this asymmetry persisted, causing the child to fall to his right side when lying on his stomach, or when sitting, and even when he started to walk.

Righting from Supine to Prone. Rolling over from back to stomach usually begins around 3 months of age. It involves a

The publication costs of this article were defrayed in part by page charge payment. This article must therefore be hereby marked “advertisement” in accordance with 18 U.S.C. §1734 solely to indicate this fact.

© 1998 by The National Academy of Sciences 0027-8424/98/9513982-6\$2.00/0 PNAS is available online at www.pnas.org.

[†]To whom reprint requests should be addressed. e-mail: teitelb@webb.psych.ufl.edu.

[§]Asymmetry can be seen briefly in many normal babies. However, if such asymmetry is persistent, a closer examination would be worthwhile.

rotation around the longitudinal axis of the body (see Fig. 11), in a corkscrew fashion, one body segment after the next. Typically, in the earliest form of such righting, the pelvis turns first, then the trunk, and finally the shoulders and head. By 6 months of age, cephalic dominance is evident (10, 11), and this order is reversed. The head turns first, and the shoulders, trunk, and pelvis follow (Fig. 1).

In our experience, impairments in righting exist in autistic infants. Some cannot turn over at all. Others, although managing to turn over, and thus “getting the job done,” do it in the following manner: starting from lying on their side (rather than on their back as normal children would do), they arch themselves sideways by raising the head and pelvis upward (Fig. 2). This narrows the base of the body so that by moving the upper leg forward that leg can serve as a weight to topple the body over. All of the segments of the body move *en bloc*, not in a corkscrew fashion. This results in the child falling over, without any active rotation.

It must be noted that, even though we have videos of 17 autistic children so far, only a few of these home videos actually filmed righting on the ground in such children. Thus, we have only a very limited sample ($n = 3$) of the righting behavior of autistic infants. However, the sideways-upward pattern of righting seen in all three of these autistic children is quite different from what normal children ever show when righting on the ground. The abnormal pattern of righting that we have just described was seen by us when the autistic children ranged in age from 6 to 9 months old. One of these children, at the age of 3 months, when lying supine, flexed his head and neck strongly forward in the midline (see Fig. 3 *a* and *b*). Such midline forward flexion can be seen in the normal newborn at the age of 5 days (9), but it is atypical for it to appear at 3 months of age. In other words, the forward-flexion pattern shown by the autistic child may be a more infantile pattern.

Sitting. Usually, at ≈ 6 months of age, a normal baby can sit upright. He maintains his equilibrium by distributing his body weight equally on his sitting bones, even when, by reaching for a toy, his upper torso will be out of the vertical. Turning his head, rocking in place, or busying his hands with objects, he maintains his stability.

Some autistic children were not able to maintain sitting stability at this age. In the extreme, he or she simply fell over like a log, without using any allied reflexes to protect himself (see Fig. 4). In other cases, where there was less severe movement disturbance, the baby managed to sit for a few minutes at a time, but, because

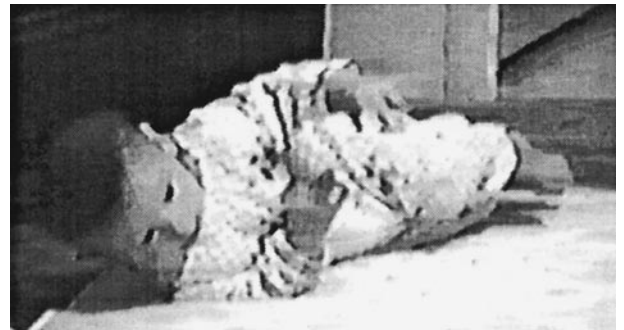

FIG. 2. An autistic baby, ≈ 5 months old, cannot right by rotation. Instead, he arches the head and pelvis sideways upward, moves the top leg forward, and topples over *en bloc*, without the sequential segmental rotation in the righting movement characteristic of normal children.

his weight often was not distributed equally on both sides, his posture was asymmetrical, leaning to one side, and he fell over when reaching for objects or moving his arms and upper body.

Crawling on Hands and Knees. Most babies start to crawl at about the same time they begin to sit. There are several forms of creeping and crawling and there is much debate about the interlimb patterning involved (see ref. 12 for a detailed discussion of this topic). We will consider here only crawling on hands and knees. The following will be used as a reference starting position: arms vertical at shoulder width, palms on the floor fingers pointing forwards; thighs vertical and hip-width apart, knees on the ground with lower legs and feet resting on the floor pointing backwards; and weight equally distributed on all four limbs (see Fig. 5). Note that this is an “ideal” position: a baby who is playing and moving around rarely will stop in this position, but it can serve as a reference relative to which other movement patterns—normal and abnormal—can be studied. When crawling forward on hands and knees, the arms and thighs move parallel to the midline axis of the body. That means that the arms stay shoulder-width apart, and so do the thighs.

Autistic Children May Show Deviations from the Normal Pattern of Crawling. *Asymmetrical lack of adequate support in the arms.* As shown in Fig. 6, this infant did not have adequate support in his arms, so that he supported himself on his forearms rather than his hands. Note that one arm is crossed in front of the other

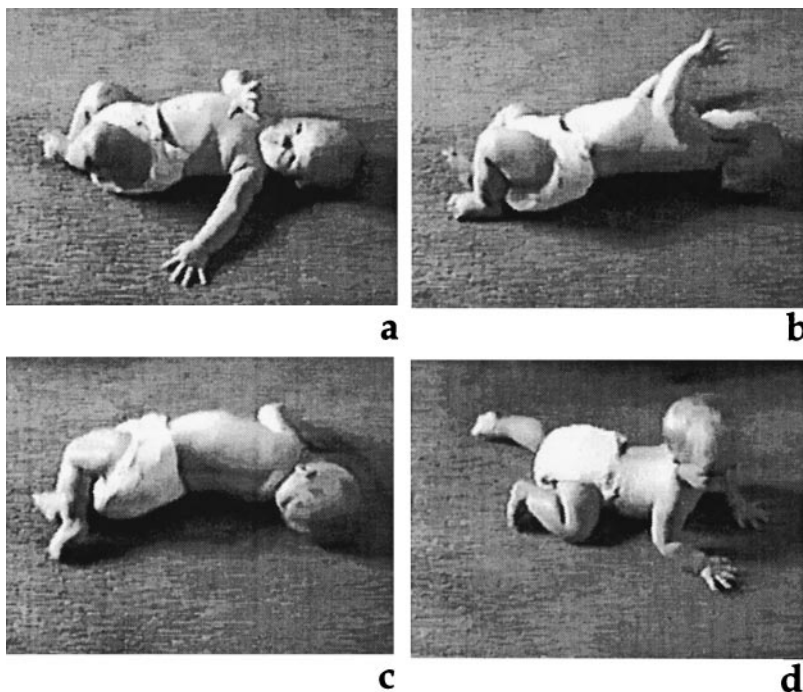


FIG. 1. A normal baby, ≈ 6 months old, shows cephalic dominance in the initiation of righting to prone when lying supine on the ground. The head turns first, and the shoulders, torso, and pelvis follow sequentially until the child reaches the prone position.

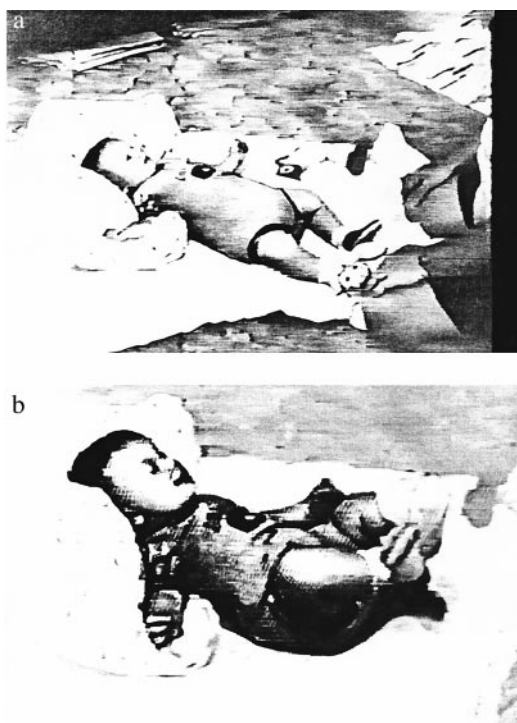


FIG. 3. An autistic child, ≈ 3 months old, lacking the ability to rotate around the body midline during righting (a), attempts to sit up by ventroflexing his body in the midline plane (b).

so that his base of support on his arms is very narrow. Although support was deficient in both arms, the right arm was weaker than the left, so that reaching was done with the left arm while the right arm often was caught under the body. He appeared to intend to crawl forward to reach the small roller on the floor in front of him. Because he could not move his thighs toward his stomach, and thus was not able to “step” forward on his knees and shift his weight, he was stuck in place. The result was that he raised his pelvis into the air while leaning on his upper arms, his body in an upside down V shape. He tried a few times to move forward by bringing his knees to the ground and pushing himself, but again and again, instead of moving forward, his knees came off the floor, extending his legs and bringing his bottom up.

Asymmetry in the legs. (i) In the next video taken of the child described above, at the age of 6 months, the arms had developed support, and the legs now could be used in crawling. However, a residual right-sided deficiency remained in the use of his legs in crawling: from the starting position described above, the left leg moved the usual way (thigh moves forward under the belly, lower leg and foot sliding on the floor) whereas the right thigh did not move actively. It was carried passively by a sideways flexion of the right hip (so that the hip came closer to the rib cage). This movement of the hip carried the thigh medially as well as forward, so that, with each crawling step, the base of the body progressively was narrowed, resulting in eventual falling over to the right.

(ii) Another autistic child is shown in Fig. 7. When this baby crawled, the left leg moved the usual way (the left thigh moved forward under the belly with the lower leg and foot sliding on the floor, and the left knee contacted the ground at the end of each step) whereas the right leg stepped forward by using the foot (the lower leg is vertical with only the foot contacting the ground at the end of each step).

Standing. A normal baby, ≈ 8 –10 months old, may pull himself up and stand for a few minutes, sometimes leaning against a piece of heavy furniture. After a short period of time, though, he typically will subside to the floor to continue his activities. One autistic girl of that age seen in Fig. 8 stood in one place leaning her back against a heavy piece of furniture for periods as long as

15 minutes at a time. Such relative akinesia may signal abnormality.

Walking. When a baby starts to walk, his gait develops through fixed stages that incorporate a proximal–distal gradient that governs the control of the different segments of the legs. The thigh, the segment of the leg most proximal to the body, is the only segment that actively moves at first. The lower leg and the foot merely are carried passively along by the movement of the thigh. They do not move actively. Later, they add their action successively. This paradigm of normal walking enables us to analyze deviations from it.

When a baby starts to walk, three stages can be differentiated. (i) **Waddling:** From a starting position of stability (see Fig. 9), in which the baby stands still, both legs parallel and weight equally distributed, the body weight is shifted laterally to one leg. This enables the other leg to lift and step forward. Because only the thigh moves actively (as in crawling, the lower leg and foot are being carried passively along), the step is very short. The foot is planted as a whole, neither toes nor heel touching the floor first. The baby then shifts his weight sideways to the leg that has just stepped, releases the other leg and brings it in a “catch-up” step to a position parallel to the leg that just had stepped. The result is a “waddling walk” in which, although the baby progresses forward, he does it by waddling from side to side, with long intervals of standing still between each pair of steps. (This can be noticed most clearly by watching the head.) The hands are raised shoulder high, forearms vertical (See Fig. 9).

(ii) **Intermediate stage:** First the step-gesture, then the shift of weight; the catch-up step is transformed into a full step forward and the step cycle develops as follows. The body weight shifts, allowing the baby to release the rear foot from the ground by rolling it from heel to toe, which, in turn, flexes the lower leg relative to the thigh. When, from this position, the lower leg swings forward, carried by the movement of the thigh, the whole leg is lowered back to the ground, the foot landing flat ahead of the other foot. Only after the leading foot has been placed on the floor is the body weight shifted forward (rather than from side-to-side as in stage i). The arms are lowered so that the upper arms hang down along the sides of the body, and the lower arms are held waist-high, parallel to the ground, pointing forward. It should be noted that, in adults with Parkinson’s disease, there is a stage of deterioration of the step cycle that parallels the form of stepping shown in this intermediate stage of the normal development of walking. Only after the leading foot is on the ground does the body weight shift forward (13).

(iii) **Final stage:** The body weight is superimposed on the step gesture; although in stages i and ii, the shift in body weight was delayed until both feet were on the ground, in this stage, weight shift occurs simultaneously with the stepping movement of the leading leg (while the leading leg is in the air). The leading foot then touches the floor heel first, and, as the rest of the foot rolls onto the floor, it acts to wheel the body weight smoothly forward. The rear heel lifts from the ground before the front foot touches the ground, enabling one to see that the weight is being shifted. The whole cycle is permitted by and permits the continuous shift of weight forward. The rolling of the foot determines the flexing of the lower leg, which then swings forward and extends to bring the heel of the flexed foot in touch with the floor. The arms are down along the sides of the body, not coordinated yet with the step cycle.

These three stages in the development of the step can be observed in every baby that starts to walk. However, the duration of each stage may vary greatly, lasting anywhere from a few days to several weeks. Also, the control of the arms may develop at different rates from that of the legs. For example, the arms may be in an advanced stage (down alongside the body), and the legs may be in stage i or ii, and vice versa.

In the gait of autistic children, the deviations from the normal can be categorized as follows. (i) **Asymmetry:** In normal walking, the movements involving the arms and legs are symmetrical. In




FIG. 4. An autistic girl, 8.5 months old, shows no allied protective reflexes when falling (e.g., extending the arms and hands out to protect herself from striking her head when falling toward the ground).

every autistic child we have seen so far, some degree of asymmetry has been found. For example, when walking, a 10-year-old girl held the right arm in a more infantile position (lower arm held at waist height, as described above) while the left arm was held downward as it swung alongside the body. When walking, a 3-year-old boy exhibited an infantile pattern in the right leg, where only the thigh was moving, carrying the lower leg and the foot with it. The other leg showed a more mature pattern; that is, all parts of the leg moved relative to one another, the heel of the foot being placed on the ground first.

(ii) Delayed development: At the age of 2 or even later, the gait may be more infantile than normal. Thus, one autistic child at the age of 2 exhibited active movement of each thigh only, with the lower leg and foot being carried passively. Also, the foot was planted on the floor as a whole, and there was no release of the hind heel and thus no smooth transfer of weight.

(iii) Sequencing, not superimposition: At the age of 5, as shown in Fig. 10, this autistic child exhibited all of the components of a "mature" step; that is, the thigh and lower leg and foot moved

actively forward, but this was done without the shift of weight that usually goes with it. Only after the leg was extended fully in the air did the shift of weight occur, so that the child fell forward on to it in a "goose step" form of walking. The shift of body weight occurred after, not along with, the movement of the leg.

(iv) The arms: In our experience, as a general rule, papers written about walking deal only with the action of the legs, omitting any discussion of the role of the arms in walking. This is unfortunate, because the action of the arms is extremely important in facilitating the gait via allied reflexes. In earlier work (13), it was shown that patients with Parkinson's disease can greatly augment the size and speed of their steps by increasing the amplitude of their arm swing. Furthermore, as described above, there are specific positions of the arms that accompany the stages of development of walking. These arm positions can serve as milestones along the course of normal development. If, in the course of development, there is arrest in an early stage (as




FIG. 5. A normal baby, \approx 6 months old, shows good support in the arms and legs while crawling forward.



FIG. 6. An autistic baby, \approx 5 months old, is unable to support himself on his hands and is unable to bring his knees toward his chest to crawl forward, so he lifts his rump up while trying to crawl but cannot move forward from the spot.



FIG. 7. An autistic baby shows asymmetry in his crawling: the left leg crawls properly, but the right foot steps rather than crawls.

signaled by the position of the arms), this can indicate abnormality. For example, in the study carried out by Vilensky, Damasio, and Maurer (3), several autistic children (ages 3–10) exhibited more infantile positions of the arms while walking: the forearm often was held parallel to the ground, pointing forward. In several cases, the arms were not held in a symmetrical position: one arm was in a more mature position (the arm fully extended downwards alongside the body) while the other was in a more infantile position (forearm held horizontal, pointing forward).

(v) Arm-and-hand flapping: Arm-and-hand flapping often can be seen in autistic children. It also can appear in normal children, usually for a few months, before it disappears. For this reason, it is difficult to use as a sign diagnostic of autism. However, if it persists to an age at which the mature form of walking should be well developed (2 years old or more), then other confirming signs should be looked for as well.

In some of the children studied here, we observed a characteristic mouth shape (see Fig. 8) called “Moebius Syndrome” (14). This mouth shape can be seen in the first few days after birth and may persist throughout infancy and on into adulthood. It does not occur in all infants who turn out to be autistic, but, when it does occur, it signals the need to observe closely the movements displayed by the infant. If some of the other symptoms of movement disorder that we have described here also occur, it strengthens the possibility that autism is involved.

DISCUSSION

Autism generally is diagnosed at ≈ 3 years of age, when a child begins to participate in organized social settings (in a nursery school, for instance). Because social skills required are aberrant in such a child, it is relatively easy to spot autistic behavior there. Such a child may not participate in social play with other children,

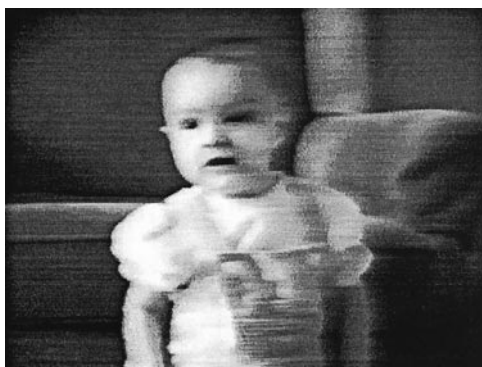

FIG. 8. Moebius Syndrome shape of the mouth in an 8.5-month-old autistic girl. The lower lip is flat, but the upper lip is arched in a characteristic shape.



FIG. 9. A normal baby, ≈ 10 months old, holds his arms up at shoulder level as he is just beginning to learn to walk.

stays by himself, and does not want to be touched by anyone. He refrains from eye contact, has difficulty expressing himself verbally, and sometimes does not talk at all. Indeed, Osterling and Dawson (15) were able to describe the deviant behaviors of autistic children by analyzing their social behavior from videos taken at their first birthday party. The problem is that, in infancy (4–6 months), the social symptoms are not so readily apparent. The infant in his crib relates largely to himself, and only his movements reflect the action of his nervous system. The child’s mother is usually aware very early that something is wrong, but, because she is unable to specify something diagnostic, the pediatrician she consults often tends to reassure her that this is a minor problem that the child will grow out of. Hashimoto *et al.* (16), using developmental delay, poor facial expression, and failure to make eye contact as indicators, were able to screen for autism at 6 months. Because it has been shown that virtually all autistic children at later ages have movement abnormalities (2, 3), we reasoned that such abnormalities might be evident in the first few months of life. As shown in the present paper, this is indeed so.




FIG. 10. (a) A 5-year-old autistic boy has a fully developed step gesture. All three segments of the leg move actively (see text), but his body weight does not shift at the same time, resulting in a form of goose-step. (b) The body weight only then is shifted so that the boy falls on the outstretched leg at each step. This is a form of sequencing rather than superimposition of one movement on the other.

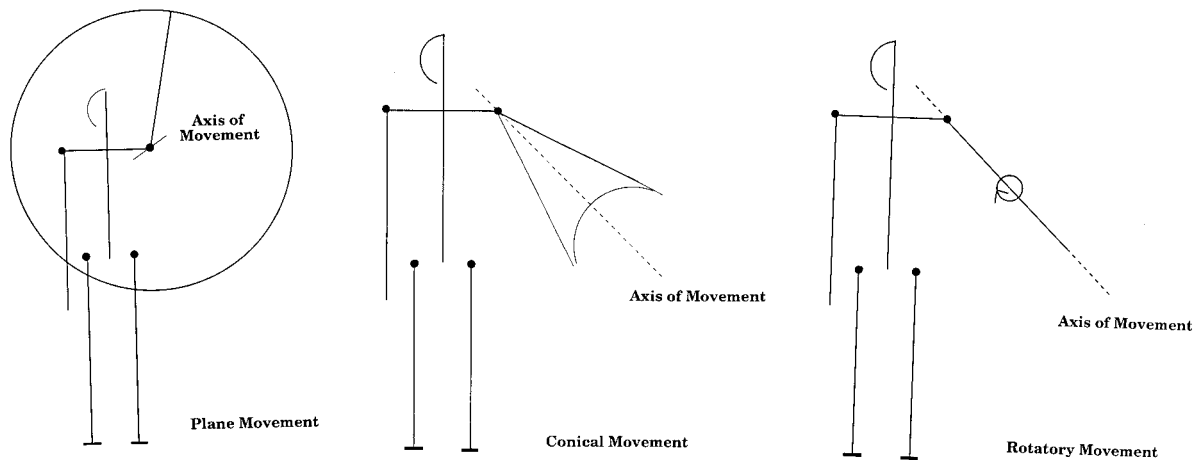


FIG. 11. A definition of the three types of movement that can be performed by the body. (*Plane movement*) The limb segment moves in a plane that is at 90 degrees to the axis of its movement. (*Rotatory movement*) The limb moves at an angle of zero degrees to its own axis: i.e., it does not move in space, but merely twists around the axis through its length. (*Conical movement*) The limb moves at an angle <90 degrees and >0 degrees to its axis of movement.

It is important that the abnormalities in movement that we have described here can be seen very early in infancy, long before the behaviors in social settings that currently form the basis for the diagnosis of autism. Diagnosis in infancy can signal the need for therapeutic behavioral interventions that might provide greater degrees of recovery from autism. Temple Grandin (17) is a famous instance of the remarkable degree of spontaneous recovery that is possible in autism. It is axiomatic that the earlier the therapy, the more effective it will be. Therefore, the fact that abnormalities in movement can be very early indicators of potential autism is important to know.

It also should be noted that the movement disturbances that we have found in autistic children typically occurred on the right side of the body. This is in contrast to the movement disturbances reported in schizophrenic children in infancy, where they occur typically on the left side of the body (18). A more detailed comparison of the movement disorders found in autistic infants with those found in schizophrenic infants would be very valuable.

The present findings are also important for pediatricians. Time and time again, in our correspondence with the mothers of autistic children, we have heard that the mother suspected that something was wrong with her baby but that the pediatrician told her that everything was all right and that she need not worry. The pediatrician should be the earliest, not the last, to know that the child might be autistic. An awareness that simple movements such as those described in the present paper might help in the diagnosis of potential autism would be valuable for pediatricians.

The fact that such early diagnosis is possible now highlights the need for the development of earlier therapies that will be effective in the treatment of potentially autistic children. Because diagnosis was not generally possible so early, no systematic methods are currently available for the treatment of infants at risk for autism. Our findings should provide the impetus for systematic search for such treatment methods.

How do we reconcile our findings of deficits in the development of movement in autistic infants with the reports from parents cited by Rimland (1) indicating that many autistic children display hyperagility and hyperdexterity? Two possibilities exist. First, it is possible that, in our limited sample of autistics, we have not achieved an adequate sample and that there exists a subgroup of autistics that display such hyperagility and dexterity even in infancy. Because we obtained our videos without asking for any special characteristics other than a diagnosis of autism, we have no reason to assume that there was a systematic bias in our sample. Alternatively, it is possible that a transformation occurs in development in autistic children, so that many of the children whose videos showed movement abnormalities in infancy might

at a later age show hyperagility and dexterity, akin to that reported by Rimland (1). This merits further investigation.

Finally, in infancy, the movement disorders present in autism are clearest, not yet masked by other mechanisms that have developed to compensate for them. It is possible that they may vary according to the areas of the brain in which developmental delay or damage has occurred. For instance, Kemper and Bauman (6) have pointed out from anatomical analysis of the brains of autistic individuals that the limbic system as well as the cerebellum may show small shrunken cells. Courchesne (4) has evidence from MRI analysis that the cerebellum may show hypoplasia or even hyperplasia in certain regions of the cerebellum. By combining movement analysis in infancy with MRI analysis, it may be possible eventually to diagnose differential areas of brain involvement in different subtypes of autism.

Note. Unfortunately, we did not have electronic versions of the figures used in this paper. We attempted to increase the clarity of the figures (which were taken directly from home videos) with numerous methods, but, because of the nature of the original images, we had little success.

We are grateful to the families who sent us the videotape material that we have analyzed in this paper. Their goodwill and cooperation made this work possible.

- Rimland, B. (1993) *Autism Res. Rev. Int.* 7, 3.
- Damasio, A. R. & Maurer, R. G. (1978) *Arch. Neurol.* 35, 777-786.
- Vilensky, J. A., Damasio, A. R. & Maurer, R. G. (1981) *Arch. Neurol.* 38, 646-649.
- Courchesne, E., Saitoh, O., Yeung-Courchesne, R., Press, G. A., Lincoln, A. J., Haas, R. H. & Schreibman, L. (1994) *Am. J. Roentgenol.* 162, 123-130.
- Piven, J., Saliba, K., Bailey, J. & Arndt, S. (1997) *Neurology* 49, 546-551.
- Kemper, T. L. & Bauman, M. L. (1993) in *Neurologic Clinics: Behavioral Neurology*, ed. Brumback, R. A. (Saunders, Philadelphia), pp. 175-187.
- Waterhouse, L., Fein, D. & Modahl, C. (1996) *Psychol. Rev.* 103, 457-489.
- Eshkol, N. & Wachman, A. (1958) *Movement Notation* (Weidenfeld and Nicolson, London).
- Casaer, P. (1979) *Postural Behavior in Newborn Infants* (William Heinemann Medical Books, London).
- Lakke, J. P. W. F. (1985) *J. Neurol. Sci.* 69, 37-46.
- Teitelbaum, P., Pellis, V. C., Chen, Y.-c., Barcsi, S. & Teitelbaum, P. (1989) *Behav. Brain Res.* 35, 241-251.
- Freedland, R. L. & Bertenthal, B. I. (1994) *Psychol. Sci.* 5, 26-32.
- Teitelbaum, P., Maurer, R. G., Fryman, J., Teitelbaum, O. B., Vilensky, J. & Creedon, M. P. (1996) in *Stereotyped Movements: Brain and Behavior Relationships*, eds. Sprague, R. L. & Newell, K. M. (Am. Psychol. Assoc., Washington, DC), pp. 167-193.
- Gillberg, C. & Coleman, M. (1992) *The Biology of the Autistic Syndromes* (MacKeith, Oxford).
- Osterling, J. & Dawson, G. (1994) *J. Autism Dev. Disord.* 24, 247-257.
- Hashimoto, T., Tayama, M., Murakawa, K., Yoshimoto, T., Miyazaki, M., Harada, M. & Kuroda, Y. (1995) *J. Autism Dev. Disord.* 25, 1-17.
- Grandin, T. & Scariano, M. (1986) *Emergence: Labelled Autistic* (Arena, Navato, CA).
- Walker, E. F., Savoie, T. & Davis, D. (1994) *Schizophr. Bull.* 20, 441-451.